

MANAGEMENT OF SEVERELY CURVED CANALS IN MANDIBULAR THIRDMOLAR: A CASE REPORT

Dr. Surabhi Parakh,¹ Dr. Vijaykumar Shiraguppi,² Dr. Bharat Deosarkar,³ Dr. Syed Tayeb,⁴
Dr. Ankur Pandey,⁵ Dr. Kiran Wanve⁶

PG student ^{1,6}, Prof. & HOD², Reader³, Senior Lecturer ^{4,5}

Department of Conservative Dentistry and Endodontics, Saraswati Dhanwantari Dental College & Hospital
& Post-Graduate Research Institute, Parbhani, Maharashtra, India.

Abstract

This article provides a case report representing management of severely curved canals in mandibular third molars. A 37-year-old patient was referred to department of conservative dentistry and endodontic for endodontic treatment of mandibular right second molar. An intraoral periapical radiograph revealed severely curved mesial canal in third molar. A wide access cavity was prepared to obtain proper visibility of the pulp chamber and the orifices followed by the use of intermediate sized files for apical preparation. Fanta S1 files were used for the biomechanical preparation as they have increased flexibility and single cone obturation was carried out. Third molars are present posteriorly and present challenges for endodontic to obtain access and handle the curvatures.

Keywords: Endo access kit, EDTA (Ethyl Diamine Tetra-acetic Acid), NaOCl (Sodium Hypochlorite, CHX (Chlorhexidine)

INTRODUCTION

Endodontic treatments of third molars are considered a challenge owing to their posterior location, inconsistent internal anatomy, and bizarre occlusal anatomy [1]. The anatomical variations encountered in third molars range from curved roots, bayonet roots, C shaped canals, fused canals etc. The prevalence of curved canals has been found to be relatively higher in mandibular molars than the maxillary molars. Curved root canals always present a difficulty during cleaning and shaping and the level of difficulty rises as the curvature of canal increases. The treatment outcome is most of times dependent on the skill of the practitioner [2]. The following article presents a case report of the endodontic treatment of a mandibular second molar with severely curved canals and highlights the various disciplines and modifications employed for its management.

CASE REPORT

A 37-year-old male patient reported to the department of conservative dentistry and endodontics with a history of sharp pain in the right lower back region for last 8 days. Clinical examination revealed a deep carious lesion in the

right mandibular third molar. Theoral findings were confirmed with an intraoral periapical (IOPA) radiograph depicting a deep carious lesion approaching the pulp in the right mandibular third molar. The IOPA radiograph further revealed curved mesial and distal canals but the curvature was greater in mesial canal than distal canal. Pulp vitality tests (cold and electric pulp test) confirmed the diagnosis of symptomatic irreversible pulpitis. The patient had an intention to save the mandibular third molar; hence, an endodontic treatment was planned for mandibular third molar. After adequate local anaesthesia and isolation with a rubber dam, the access cavity was prepared using Endo Access kit (Dentsply) in the mandibular right third molar. After gaining an adequate access, initial scouting of all the root canals was done with K-file no. 10, and the patency of root canals was established. Gates Glidden (GG) drills to allow easy placement of instruments and to gain a straight-line access to the apex. The working length was confirmed using an apex locator (Eighteenth E-pex, orikam) and SS K-file no. 15 through an RVG (Figure 1). Succeeding, path finder files (Dentsply) of intermediate sizes, i.e., no. 13, no. 16, and no. 19, were used in order to closely follow the curvature and maintain the apical spatial orientation. Each

filing sequence was accompanied with 17% EDTA followed by copious irrigation with saline and 5.2 % NaOCl. The rotary Fanta S1 files were subsequently used in the fashion as instructed by the manufacturer (20-0.4, 20-0.6). Following the biomechanical preparation, the canals were irrigated, flushed with Chlorhexidine 2% and EDTA 17%, and dried prior to obturation. Single cone 6% taper gutta percha cones were used to obturate all the canals (Figure 2). The post obturation restoration was done with a composite to maintain a good coronal seal (Figure 3).

DISCUSSION

Endodontic treatment of third molars is generally challenging as there is presence of curved canals, fused roots and C-shaped canals has been reported in the literature. The prevalence of curved canals has been found to be relatively higher in mandibular molars, ranging from 3.3 to 30.92% when compared to maxillary molars that range from 1.33 to 8.46%. A tooth is considered dilacerated when there is a mesial or distal tilt of the root and the angle is equal or exceeds 90° in relation to the tooth or root axis. Another school of thought considers a dilaceration when its apical deviation is equal or exceeds 20° in relation to the normal tooth axis [5]. Root canal curvatures may be apical, gradual, sickle shaped, severe-moderate-straight curve, bayonet/S-shaped curve, and dilacerated curve [6]. Curved root canals present a challenging situation for cleaning, shaping and disinfection of the particular third molar [7]. These curves must always be valued and maintained strictly. The clinical strategy alters with the degree of dilacerations. Various attempts have been made to measure the extent of curvatures. The most accepted one is given by Schneider. This method involves drawing a line parallel to the long axis of the canal in the coronal third of the root canal and another line drawn from the apical foramina to intersect the first line on a hard copy of the diagnostic radiographic printout. Schneider's angle is formed from the intersection of these lines. Accordingly, the degree of root canal curvature is categorized as straight: 5° or less, moderate: $10-20^{\circ}$ and severe: $25-70^{\circ}$.

Gunday et al. introduced the term "canal access angle" (CAA), a parameter which provides more information about the coronal geometry of canal curvature. [8] Abiding by Schneider's method, the aforementioned third molar exhibited severe dilacerations (Figure 1) and demanded a cautious preparation at each step. While preparing the curved canals, the following principles were closely followed:

- (1) To maintain the apical foramen in its original location.
- (2) To gain a proper straight-line access to the site of curvature.
- (3) To respect the anatomical danger zone in curved canals: the inner wall of the middle third and outer aspect of the apical third.
- (4) To use an instrument that will closely adapt to the original shape of the canal [9].

CONCLUSION

Treatment of curved mandibular third molar is always a challenging case due to the presence of anatomical variations encountered but still it can be done precisely by following the basic rules. We should always take the advantage of new techniques in endodontics such as using intermediate pre curved files along with the flexible rotary systems that are available to treat the challenging cases as it is mentioned in this case report.

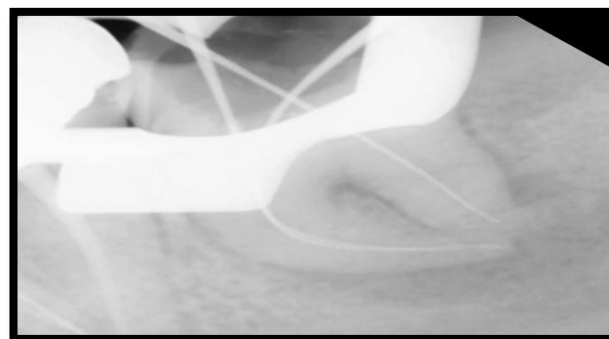


Figure 1 Working Length Determination

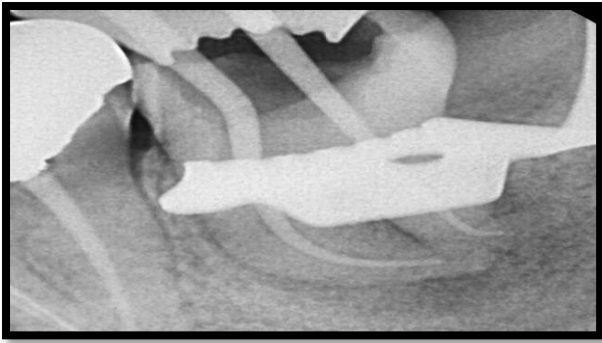


Figure 2 Master cone determination

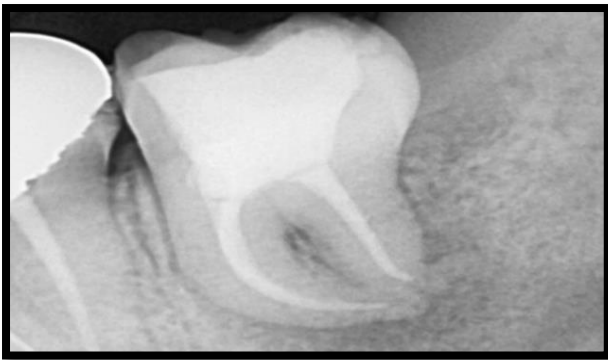

Figure 3 Postoperative radiograph

REFERENCES

- 1) Ahmed HM. Management of third molar teeth from an endodontic perspective. *European journal of general dentistry*. 2012 Sep 1;1(3):148.
- 2) Ćosić J, Galić N, Vodanović M, Njemirovskij V, Šegović S, Pavelić B, Anić I. An in vitro morphological investigation of the endodontic spaces of third molars. *Collegium antropologicum*. 2013 Jul 1;37(2):437-42.
- 3) Gulabivala K, Opasanon A, Ng YL, Alavi A. Root and canal morphology of Thai mandibular molars. *International endodontic journal*. 2002 Jan;35(1):56-62.
- 4) Hamasha AA, Al-Khateeb T, Darwazeh A. Prevalence of dilaceration in Jordanian adults. *International endodontic journal*. 2002 Nov 1;35(11):910-2.
- 5) Schneider SW. A comparison of canal preparations in straight and curved root canals. *Oral surgery, Oral medicine, Oral pathology*. 1971 Aug 1;32(2):271-5.
- 6) Jain N, Tushar S. Curved canals: ancestral files revisited. *Indian Journal of Dental Research*. 2008 Jul 1;19(3):267.
- 7) Vertucci FJ. Root canal morphology and its relationship to endodontic procedures. *Endodontic topics*. 2005 Mar;10(1):3-29.
- 8) Gunday M, Sazak H, Garip Y. A comparative study of three different root canal curvature measurement techniques and measuring the canal access angle in curved canals. *Journal of endodontics*. 2005 Nov 1;31(11):796-8.
- 9) Jafarzadeh H, Abbott PV. Dilaceration: review of an endodontic challenge. *Journal of endodontics*. 2007 Sep 1;33(9):1025-30.
- 10) J. L. Guttman, *Problem Solving in Endodontics*, Mosby - Year book Inc, Missouri, 3rd edition, 1997.
- 11) Yu DC, Schilder H. Cleaning and shaping the apical third of a root canal system. *General dentistry*. 2001;49(3):266-70.
- 12) Pereira ÉS, Peixoto IF, Nakagawa RK, Buono VT, Bahia MG. Cleaning the apical third of curved canals after different irrigation protocols. *Brazilian dental journal*. 2012;23(4):351-6.

Corresponding Author Details:

Dr. Surabhi Parakh, PG students, Department of Conservative Dentistry Saraswati Dhanwantari Dental College & Hospital & Post Graduate Research Institute, Parbhani, Maharashtra, India.