

INTERDISCIPLINARY PERIODONTICS- ENHANCING MULTIDISCIPLINARY APPROACH OF TREATMENT PLANNING IN DIFFERENT STREAMS-PART I

Dr. Prachee Hendre¹, and Dr. Roshani Thakur²,
Senior Lecturer ¹, Prof. and HOD².

Department of Periodontics,
Saraswati Dhanwantari Dental College & Hospital & Post Graduate Research Institute, Parbhani,
Maharashtra, India.

Summary- In this article we would like to discuss the interactions and interrelationships of periodontal treatments and periodontal diseases with other streams of dentistry and medicine. Frequently many patients are seen to have multiple dental needs or systemic health issues which need a combined management like endodontics, esthetics, fixed prosthodontics, radiology, orthodontics, paediatric dentistry, oral and maxillofacial surgery, oral pathology and general medicine.

Hence, it is concluded to show how and why periodontal treatment should be interdisciplinary and that this approach is beneficial for better treatment benefits.

Keywords- Multidisciplinary, Interdisciplinary, Periodontics, Periodontal treatment.

Introduction

Understanding the interaction between different streams of dentistry is essential for the clinicians as it becomes challenging to achieve a diagnosis, plan a treatment and predict the prognosis of combined treatments in periodontal diseases. In few cases although periodontal treatments do not have a direct effect on the treatment outcome but, harmony between the treatment outcome and periodontium is essential like in esthetics or in longevity of the restorations etc.

(1) Some systemic diseases have also shown a direct or indirect effect on the periodontal health and vice versa. Hence, referrals to general physicians and periodontal referrals from the general

physicians are seen to play a crucial role in patient management of periodontal diseases with underlying systemic ailments. The interaction between periodontics and endodontics is of crucial importance due to the combined Endodontic-Periodontics lesions. Common etiologic and contributing factors like the Microorganisms, trauma, root resorptions, perforations, fractures, play their part in progression of these diseases. Esthetic considerations are significant, as visible soft-tissue architecture plays a key role in developing an esthetic smile.

(2) The Prosthodontics treatment enhances patient's comfort, function, esthetics and health. Longevity of prosthodontic restorations majorly depends on the cleans-

ability of the restoration and hence depends on the periodontic and prosthodontic relationship. This treatment should not induce damage to the periodontal structures.

(3) Periodontal therapeutic options frequently require an imaging modality capable of providing a diagnostic osseous baseline. It facilitates both smaller addition and subtraction changes in the bony architecture and levels. Intraoral and panoramic, are the modalities most commonly used to identify the alterations in the pattern of marginal alveolar bone loss and to determine the response to therapy. Since, these two provide only a 2D imaging, the CBCT imaging offers specific advantages for periodontal therapies in which 3D images of dental and marginal tissues can be rendered with greater accuracy in single procedure. (4)

The close and intricate relationship between periodontium and the process of tooth movement suggest that adjunct orthodontic therapy plays a key role in overcoming the challenges faced by the clinicians during rehabilitation of periodontally compromised dentitions. Also, extreme movements of teeth beyond anatomic jacket contribute to further destruction of periodontal tissues. Hence, interaction between these two streams becomes essential. (5) In paediatric patients their oral health reflects their general health. There are potential health problems associated with the dental health of children entering adulthood which need alteration in the overall treatment required for children, especially in the stage of eruption of dentition and mixed dentition stage.

(6) The boundary lines between oral surgical procedures being limited, bind the different

specialities like oral and maxillofacial surgery and periodontology. Hence, routine inclusion of both periodontists and oral and maxillofacial surgeons in the interdisciplinary management of dental patients' needs to be highlighted.

(1) The gingival and periodontal tissues are involved in many local and systemic conditions. Some of these conditions affect one or more components of the human systems. It should be ensured that such lesions be diagnosed and treated in a timely manner. (1)

Identifying and treating the diseases related to oral health and overall health of the individual is crucial. This is because dental treatment becomes essential for diseases like infective endocarditis, suboptimal glycemic control and deterioration of renal and reproductive functions. Such medical conditions to which patients are predisposed as a result of poor dental hygiene need to be examined and referred immediately. Hence, a strong relationship within a dentist and physician needs to be built up. (7) Endodontics and Periodontics In endodontic and periodontic interaction, following pathways are likely to be considered ;(2) the anatomical considerations, disease relationship via the etiology & progression of the disease, common contributing factors like treatment failures and developmental anomalies. The differential diagnosis and prognosis of the treatment depends primarily on these mentioned factors.

The dental pulp and the periodontium are very closely related in various pathways like the exposed dentinal tubules (fig 1), apical foramens and lateral and accessory canal openings. (1) Exposure of dentinal tubules may be due to developmental

defects, diseases or periodontal or surgical procedures. (8) It may also occur at sites where cementum and enamel don't meet. Patients experiencing cervical dentin hypersensitivity are an example of such a phenomenon. Fluid and irritants may flow through patent dentinal tubules and, in the absence of an intact covering of enamel or cementum, the pulp may be considered as exposed to the oral environment via the gingival sulcus or periodontal pocket. (1) Small portals of exit can be present along the complete length of the root. Canals in the furcation region can also act as a direct communication between pulp and the periodontium. But all canals do not extend to the full length from the pulp chamber to the floor of the furcation. (9) Seltzer et al have reported that these small portals of exit bear the potential to spread micro-organisms and their toxic products from pulp to the PDL and vice-versa. (Fig. 2) (10)

Common etiological causes play a crucial role in pulpo-periodontal disease relationships and their treatment. Live pathogens and infectious biofilms containing bacteria along with other microorganisms like the viruses, including EB virus type I or HCMV is observed to contribute along with HIV in 65% of periodontal pocket formation. (11) Studies have also shown presence of common species of herpes viruses in the pulp of the teeth and periradicular tissues of diseased teeth. (12) The presence of fungi (yeasts) is associated with endodontic diseases, in untreated root caries, dentinal tubules, failing RCTs, apices of the teeth with asymptomatic apical periodontitis. (1) *Candida* sp. have been detected in 21% of infected root canals and periradicular tissues. (13) Also, it is observed, that approximately 20% of adult

patients with periodontitis harbour sub gingival fungi and more common species among them is the *Candida* sp. These pathogens and their by-products can affect the periodontium in a variety of ways and need to be eliminated during root-canal treatment. (14) Other than the living pathogens, certain non-living pathogens; extrinsic or intrinsic can also be the contributing factors depending on their nature and origin. (1)

Extrinsic nonliving pathogens, depending on their origin and nature, are the foreign bodies often found to be associated with the inflammatory process of the periradicular tissues. Possible culprits include substances such as dentin and cementum chips, amalgam, root-canal filling materials, cellulose fibers from absorbent paper points, gingival retraction cords, leguminous foods and calculus-like deposits. Intrinsic are those present in the host tissues for example, epithelium, cholesterol, Russell's bodies, crystals etc.

Other various contributing factors also play a role to dramatically alter the disease progression. These can be enlisted as poor endodontic treatment, poor restorations, trauma, perforations and developmental malformations.

To achieve a differential diagnosis and establish a treatment of lesions caused by such multiple etiologies the following classification is proposed by Rotstein et al in 2006. (15) It includes, (i) primary endodontic diseases; (ii) primary periodontal diseases; and (iii) combined diseases. The combined diseases include, (i) primary endodontic

disease with secondary periodontal involvement; (ii) primary periodontal disease with secondary endodontic involvement; and (iii) true combined disease. This classification is based on theoretic pathways forming radiographic lesions. If the lesion shows final involvement they show similar radiographic readings and differential diagnosis and thereby the treatment becomes challenging.

Figures




Fig. 1. (A) Scanning electron micrograph of open dentinal tubules. (B) Higher magnification demonstrates the absence of odontoblastic processes. (Lyons & Darby 2017)

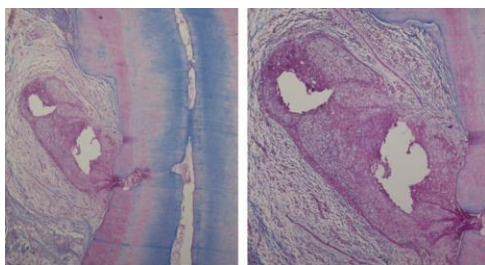


Fig. 2. Micrograph of a maxillary lateral incisor with a necrotic pulp associated with a lateral inflammatory process in the periodontal ligament. (A) Main canal, accessory canal and the resultant inflammatory response in the periodontal ligament are evident. (B) Higher magnification of the area shows chronic inflammation with proliferating epithelium. Masson's trichrome stain. (Lyons & Darby 2017)

The treatment of endodontically involved diseases is root canal treatment.(15) The sinus tract usually disappears at an early stage of pulpectomy followed by well prepared and obturated root canals. Periodontally involved lesions can be treated without pulpal treatments. The prognosis of the periodontal treatment

depends on the stage of the periodontal disease and efficacy of periodontal treatment. The main factors to consider for treatment decision-making are pulp vitality and type and extent of the periodontal defect. (1)

Esthetics in Periodontics

Before initiation of this discussion it is important to note that though there are a number of guidelines provided for esthetic preparations, deviations from ideal do not necessarily lessen the beauty of one's smile.(16) Therefore, from an esthetic perspective, the parameters assessed are as follows; (i) periodontal status of the underlying bone, (ii)the gingiva, (iii)the interdental papilla/pink esthetic component, (iv)the teeth/white esthetic component and (v)the biologic space.(17)

Treatment planning from an esthetic consideration can be achieved under following parameters namely, gingival phenotypes, gingival contours, condition of the zone of attached gingiva and papillary contours for the soft tissue element. The hard tissue element of this treatment form consists of several parameters of the crown in relationship to the supporting gingival form.

Soft tissue considerations

Gingival phenotype

Pontoriero et al in 2001, in their clinical study concluded that gingival biotypes, thick and thin, flat and scalloped, is responsible for predictable results after root coverage procedure and resective osseous surgeries. The thick gingival biotype shows better predictable results than a thin biotype which results in lower probability of a complete root coverage (CRC).(18)

Gingival contours

The key factors to plan esthetic treatments are harmony and symmetry. The gingival topography conducive to final esthetic outcome is the aim that should be planned before the procedure. The matching of the gingival zenith and the height of contour of gingival margin are the two important parameters from esthetic point of view. (17)

Zone of attached gingiva

Miyasato et al in their study have reported that even in a minimal zone of attached gingiva, the periodontal health can be preserved if a good oral hygiene is maintained. The current consensus states that in the presence of good oral hygiene a minimal width of attached gingiva has no significant consequences on periodontal disease. In other words, there is no evidence of periodontal loss or the periodontium being more prone to inflammation due to narrow zone of attached gingiva than a wider zone.(20)

The significance of attached gingiva is more important to minimise the risk of gingival recession while preparing esthetic margins and to increase patient comfort while performing oral hygiene procedures.(21)

Gingival biotype is one factor that must be considered while planning restorative treatment especially in the anterior maxillary teeth, as the thin gingiva entirely shows inflammation and hence leads to rapid recession.(22)

Papillary contours

According to Cho et al, factors like age, tooth shape, interdental contact length, gingival thickness and distance from the contact point to the alveolar crest with

papilla dimensions are associated with establishment of papillary contours. They have found that long narrow teeth e.g. the anteriors, contribute to more papillary deficiency whereas teeth with a square flat contact favoured occurrence of more papilla. Hence, the position of the contact point relative to the alveolar crest is of importance in maintaining and reconstructing the interdental papilla.(23)

Hard-tissue considerations

It is logical to estimate the prosthetic crown contour to be approximated to that of the natural tooth in shape. But in order to do so, care should be taken that the natural tooth contour is not increased more than 0.5mm from the gingival margin especially

when closing the diastema in open gingival embrasures. One limitation to this is also the close approximation of teeth in question as alteration cannot be carried in roots with closer approximation.(24)

The location of the interproximal area also is a critical factor in esthetic evaluation that is defined by the incisal/gingival embrasure and height of the interdental papilla.(25) Hence, both location and dimensions of the interproximal contact should be considered while restoring the teeth in laboratory or in clinical setting.

Choice of periodontal surgical technique

This choice depends on the anatomical characteristics of the area like, the tooth location, multiple or single periodontal defect(recession), interdental attachment level, amount and thickness of keratinized tissue apical and/or lateral to recession, vestibular depth, height and width of the recession defect.(26)

Table 1. Decision aid model for root coverage surgery (single recession)^a

Procedure	Miller Class I	Miller Class II	Miller Class III	Wide defect	Deep defect	Thick keratinized tissue	Thin keratinized tissue
Coronally positioned flap or semilunar coronally repositioned flap	+	-	-	-	-	+	-
Connective tissue graft+coronally positioned flap	+	+	+	+	+	+	+
Enamel matrix derivative+coronally positioned flap	+	+	+	+	-	+	+
Barrier membranes+coronally positioned flap	+	+	+	+	-	+	+
Laterally repositioned flap	+	-	-	-	-	+	-
Guided tissue regeneration	+	+	+	+	-	+	-

Effects of Orthodontic treatment on Periodontium

An increasing number of adult patients are seeking orthodontic treatments, most of whom have a periodontal disease. periodontal disease is not a contraindication to orthodontics movements per se, provided that the periodontium is stabilized. A critical

issue in the treatment planning of any patient revolves around the fact how much orthodontic movement the periodontium can tolerate before it becomes adversely affected. The periodontal tissue is seen responding differently to different treatment mechanics. (27)

The envelope of tooth movement

It is seen that limits of tooth movement are defined by strict physiologic and anatomic boundaries like the anatomy of the alveolar bone, pressures of the soft tissues, periodontal tissue attachment levels, neuromuscular forces and lip-tooth relationships. (28) Large movements of the teeth beyond the “envelope of discrepancy” are possible with favourable remodelling of the facial skeleton by orthognathic surgery. (Fig. 3). (29) It is suggested that adults with severe crowding and reduced periodontium

can be successfully treated by moving the teeth beyond the envelope of the alveolar process, given that well-controlled force systems are used. (30)

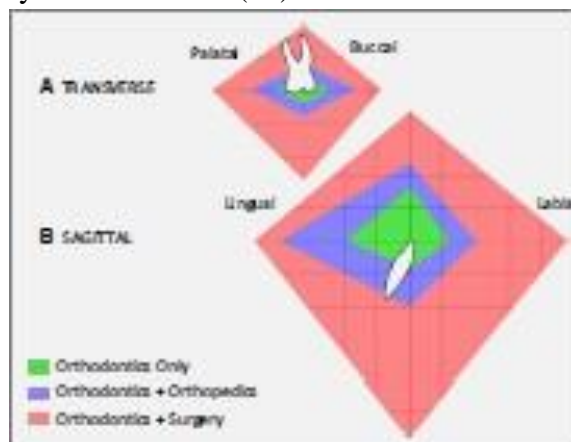


Fig. 3. Conceptual illustration of the ‘envelope of discrepancy’. Colored polygons represent the biologic boundaries of tooth movement for orthodontic treatment only (green zone), orthodontic treatment and dentofacial orthopedics (blue zone) and orthodontic treatment and orthognathic surgery (red zone). (A) Transverse tooth envelope for maxillary posterior teeth. (B) Sagittal tooth envelope for mandibular anterior teeth. Modified from Graber et al. (29).

Tissue response to orthodontic forces

It is known that areas of tension undergo bone apposition and that under compression undergo bone resorption. But recently it is believed that the distribution of compressive and tensile

Strains in periodontal tissues is more complex than that believed previously. Animal models have shown the periodontal ligament on the compression side may appear either normal or disorganized. (31)

The applied forces play a role in determining the pattern of stresses and strains in the dento-alveolar tissues. The tooth may move ‘through’ or ‘with’ the bone. The tooth moves through the bone when undermining resorption occurs in response to heavy forces which cause localized areas of necrosis in the periodontal ligament. Undermining resorption is typically characterised by a delay in tooth movement until the necrotic tissue has been

completely removed. (32) The relationship between force magnitude and type of resorption that occurs on the pressure side are clear to orthodontists since a long time. (32) Movement of teeth through bone, for example, may be desirable in cases where the clinician is interested in extruding a root-fractured tooth without the accompanying bone. On the other hand, movement of teeth with bone may help augment bone as teeth are moved into sites with atrophic alveolar ridges (33).

Conclusion

The objectives of such reviews is to identify important patient and treatment-related factors that may influence the response of periodontal tissues to specific treatment modalities and vice-versa. A healthy periodontium is a prerequisite for success with any dental treatment. Without a strong interdisciplinary relationship between periodontics and prosthodontic, esthetic, endodontic and orthodontic modalities, the treatment outcome may be compromised and necessitate extensive and expensive retreatment. Hence while planning treatments, consideration should be given to periodontal factors even if they do not have a direct effect on the final modality. But the longevity of the prosthesis, esthetic emergence profile are critically controlled by the periodontal treatments.

Hence, to achieve a predictable successful outcome a comprehensive examination and accurate diagnoses that are subsequently used to generate an appropriate treatment plan are critical and should be considered in detail.

References

1. Lyons K & Darby I. Interdisciplinary periodontics: the multidisciplinary approach to the planning and treatment of complex cases. *Periodontology* 2000. 2017;74:7–10.
2. Rotstein I. Interaction between endodontics and periodontics. *Periodontol* 2000.2017;74:11–39.
3. Abduo J, Lyons KM. Interdisciplinary interface between fixed prosthodontics and periodontics. *Periodontol* 2000.2017;74:40–62.
4. Scarfe WC, Azevedo B, Pinheiro LR, Priaminiarti M, Sales MAO. The emerging role of maxillofacial radiology in the diagnosis and management of patients with complex periodontitis. *Periodontol* 2000.2017;74:116–139.
5. Antoun JS, Mei L, Gibbs K, Farella M. Effect of orthodontic treatment on the periodontal tissues. *Periodontol*2000.2017;74:140–157.
6. Drummond BK, Brosnan MG, Leichter JW. Management of periodontal health in children: pediatric dentistry and periodontology interface. *Periodontol*2000.2017;74:158–167.
7. Chan S, Maurice AP, Pasternak GM, West MJ. The place of periodontal examination and referral in general medicine. *Periodontol* 2000.2017;74:194–199.
8. Zachrisson BU, Jacobsen I. Long- term prognosis of 66 permanent anterior teeth with root fracture. *Scand J Dent Res*.1975;83:345–354.
9. Goldberg F, Massone EJ, Soares I, Bittencourt AZ. Accessory orifices: anatomical relationship between the pulp chamber floor and the furcation. *J Endod*.1987;13:176–181.
10. Seltzer S, Bender IB, Ziontz M. The interrelationship of pulp and

- periodontal disease. *Oral Surg Oral Med Oral Pathol.*1963;16:1474–1490.
12. Glick M, Trope M, Pliskin ME. Detection of HIV in the dental pulp of a patient with AIDS. *J Am Dent Assoc.*1989;119:649–650.
 13. Sabeti M, Simon JH, Nowzari H, Slots J. Cytomegalovirus and Epstein-Barr virus active infection in periapical lesions of teeth with intact crowns. *J Endod.*2003; 29:321–323.
 14. Baumgartner JC, Watts CM, Xia T. Occurrence of *Candida albicans* in infections of endodontic origin. *J Endod.*2000;26:695–698.
 15. Hannula J, Saarela M, Alaluusua S, Slots J, Asikainen S. Phenotypic and genotypic characterization of oral yeasts from Finland and the United States. *Oral Microbiol Immunol.*1997;12:358–365.
 16. Rotstein I, Simon JHS. The endo-perio lesion: a critical appraisal of the disease condition. *Endod Topics.*2006;13:34–56.
 17. Saadoun AP. The dentoalveolar gingival unit. Esthetic soft tissue management of teeth and implants. Chichester, West Sussex, UK: A John Wiley & Sons Ltd.2012;20–65.
 18. Bennani V, Ibrahim H, Al-Harhi L, Lyons K. The periodontal restorative interface: esthetic considerations. *Periodontology* 2000.2017;74:74-101.
 19. Pontoriero R, Carnevale G. Surgical crown lengthening a 12-month clinical wound healing study. *J Periodontol.*2001;72:841–848.
 20. Miyasato M, Crigger M, Egelberg J. Gingival condition in areas of minimal and appreciable width of keratinized gingiva. *J Clin Periodontol.*1977;4:200–209.
 21. Miyasato M, Crigger M, Egelberg J. Gingival condition in areas of minimal and appreciable width of keratinized gingiva. *J Clin Periodontol.*1977;4:200–209.
 22. Goldberg P, Higginbottom FL, Wilson TG. Periodontal considerations in restorative and implant therapy. *Periodontol* 2000.2001;25:100–109.
 23. Baker D, Seymour GJ. The possible pathogenesis of gingival recession. *J Clin Periodontol.*1976; 3:208–219.
 24. Cho H, Jang HS, Kim DK, Park JC, Kim HJ, Choi SH, Kim CK, Kim BO. The effects of interproximal distance between roots on the existence of interdental papillae according to the distance from the contact point to the alveolar crest. *J Periodontol.* 2006; 77:1651–1657.
 25. Kois JC. The restorative-periodontal interface biological parameters. *Periodontol* 2000.1996; 11:29–38.
 26. Nelson S. Wheeler’s dental anatomy, physiology and occlusion. Chicago: Elsevier Health Sciences,2015.108.
 27. de Sanctis M, Clementini M. Flap approaches in plastic periodontal and implant, surgery: critical elements in design and execution. *J Clin Periodontol* 2014; 41(S15): S108–S122.
 28. Antoun J, Mei L, Gibbs K, Farella M. effects of orthodontic treatment on the periodontal tissues. *Periodontol* 2000.2017;74:140-157.

30. Ackerman JL, Proffit WR. Soft tissue limitations in orthodontics: treatment planning guidelines. *Angle Orthod.*1997;67:327–336.
31. Cirelli CC, Cirelli JA, da Rosa Martins JC, Lia RC, Rossa C Jr, Marcantonio E Jr. Orthodontic movement of teeth with intraosseous defects: histologic and histometric study in dogs. *Am J Orthod Dentofacial Orthop.*2003; 123:666–673.
32. Bassarelli T, Melsen B. Expansion: how much can the periodontium tolerate? *Clin Orthod Res.*2001;4:235–241.
33. Cattaneo PM, Dalstra M, Melsen B. The finite element method: a tool to study orthodontic tooth movement. *J Dent Res.* 2005;84:428–433.
34. Melsen B. Biological reaction of alveolar bone to orthodontic tooth movement. *Angle Orthod.*1999; 69: 151–158.
35. Melsen B, Agerbaek N. Orthodontics as an adjunct to rehabilitation. *Periodontol 2000.* 1994;4: 148–159.

Corresponding Author Details:

Dr. Prachee Hendre, Senior Lecturer,
Department of Periodontics, Saraswati
Dhanwantari Dental College & Hospital
& Post Graduate Research Institute,
Parbhani, Maharashtra, India.