

Pyogenic granuloma- A case report

Komal B Dipke¹, Namrata Patil², Vinita Murgod³, Mangala Rakaraddi⁴, Neha Kharwade⁵,
Akanksha Shirdhonkar⁶

From PG Student ¹, Prof & Head ², Prof ³, Department of Oral and Maxillofacial Pathology and Microbiology, Prof & HOD ⁴, PG Student ⁵, Department of Oral Medicine and Radiology, PG Student ⁶, Department of Periodontics and Implantology, Saraswati Dhanwantari Dental College and Hospital and Post Graduate Research Institute, Parbhani, Maharashtra, India

Abstract: Pyogenic granuloma is one of the inflammatory hyperplasia seen in the oral cavity. Etiological factors of pyogenic granuloma may be underlying irritating factor such as local irritation, traumatic injury or hormonal factor. Clinically it is seen as a smooth exophytic, pedunculated or sessile hemorrhagic base. Cases with this condition are associated with discomfort, sometimes it interfere with mastication and poor aesthetics. This paper presents a case of pyogenic granuloma managed by surgical interventions.

Introduction-

Pyogenic granuloma (PG) is a benign non neoplastic lesion in the oral cavity and it is relatively common in occurrence on gingiva[1]. It is also called as pregnancy tumour as it has 5% of increased incidence during pregnancy [2].Hartzell in 1904 coined the term pyogenic granuloma. In 1844 Hullihen's reported the first case of pyogenic granuloma [3].Pyogenic granuloma most commonly seen in maxilla than mandible and is more common in anterior region than posterior region [4]. Pyogenic granuloma is most frequently seen on gingiva and rarely seen on buccal mucosa, lip, palate, tongue. Clinically it is seen as smooth, exophytic painless, pedunculated mass of gingival [3]. The lesion bleeds easily on slight provocation and its size varies from few millimetres to few centimetres.[5,2]

Histologically, there are two types of pyogenic granuloma namely, lobular capillary haemangioma and non lobular capillary haemangioma [6].The development of gingival PG may also be related to hormonal changes (puberty, menstruation pregnancy) [7].

Many lesions occurring in the oral cavity have similar appearance to pyogenic granuloma. To point out the correct disease a detailed history, clinical examination and a proper treatment plan will be helpful. This case report presents a case of pyogenic granuloma in a 64 year old female patient managed by surgical interventions.

Case report-

A 64 year old female patient with chief complaint of overgrowth in upper front region of jaw came to the outpatient department at our institute.

Patient was apparently alright before 6 months then she noticed overgrowth on the maxillary anterior teeth region. Overgrowth increased gradually. Patient was also concerned about her compromised aesthetics. Extraoral examination revealed the proclination of upper lip and incompetence of lip due to overgrowth. Intraoral examination revealed lesion in upper anterior edentulous region in relation to teeth 21 and 22. Grade III mobility seen with respect to 23 and 24. Overgrowth was single, reddish pink in colour ovoid in shape and size of 2×1 cm soft in consistency with pedunculated base and bleeds on slight provocation. Based on clinical features provisional diagnosis pyogenic granuloma was made.

Periapical radiograph was taken that didn't reveal any change. Routine hematologic tests were done which were within the normal range. The lesion was excised under local anaesthesia and was sent for histopathological evaluation.

Histopathological examination under low power view showed stratified squamous parakeratinized epithelium of varying thickness and underlying connective tissue stroma with thick bundles of collagen fibres and numerous blood vessels. On high power view connective tissue stroma containing numerous collagen fibres with proliferating fibroblast, numerous blood vessels with plump endothelial cells were seen. Numerous budding capillaries were seen. Dense chronic inflammatory cells like lymphocytes and plasma cells seen. These all findings are suggestive of pyogenic granuloma.

Patient is recalled after 7days, 1 month and 3 month for follow up and no recurrence was found.

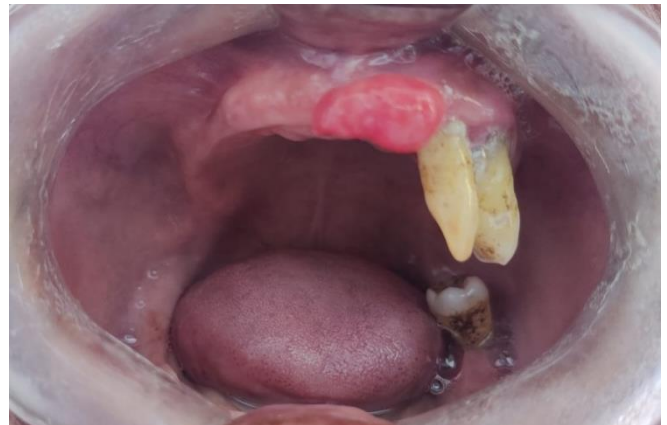

Figure 1 pyogenic granuloma of gingiva

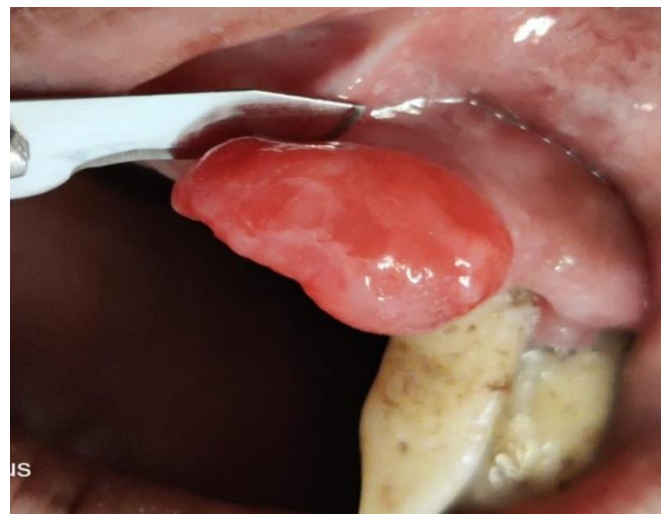

Figure 2 pyogenic granuloma

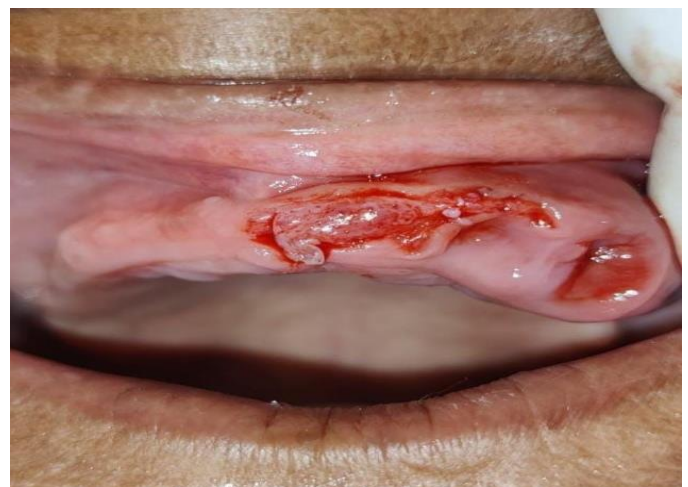

Figure 3 immediate post operative

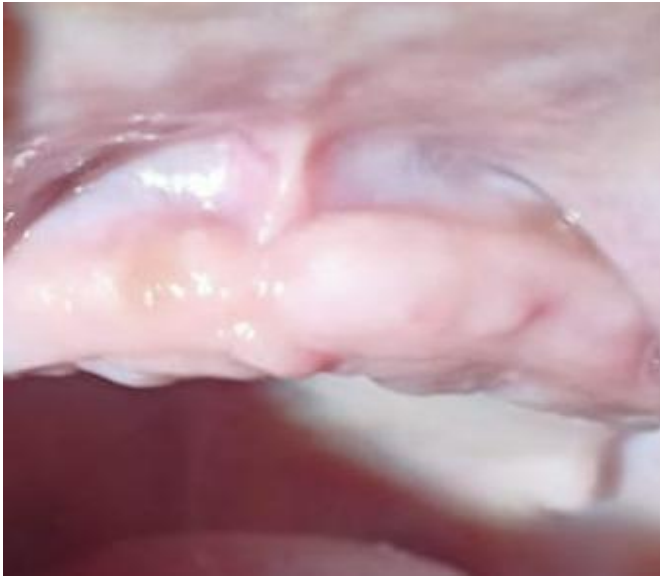

Figure 4 follow up

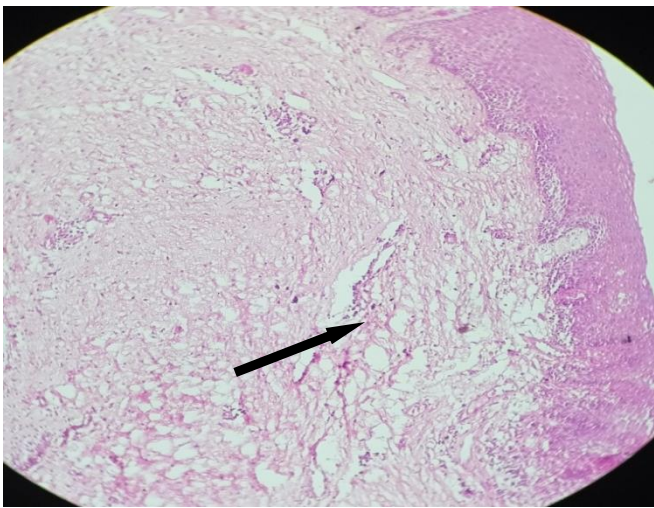


Figure 5 histopathological picture of pyogenic granuloma arrow showing blood vessels

Discussion

In 1844 Hullihen reported the first case of pyogenic granuloma in English literature. Hartzell in 1904 coined the term pyogenic granuloma. Clinically pyogenic granuloma is soft, painless, pedunculated or sessile, exophytic and reddish purple in colour. Intraorally, most common site for occurrence of pyogenic granuloma is gingival

followed by lip, tongue, buccal mucosa and hard palate [3]. Pyogenic granuloma is most frequently seen in maxillary anterior region than mandibular anterior region [4].

Pyogenic granuloma is most commonly seen in second decades of life usually in female patient due to vascular effect. Increased level of oestrogen and progesterone during pregnancy increases the incidence of pyogenic granuloma during pregnancy [7]. Other causes include minor injury or irritating factors like calculus, poor oral hygiene, non specific infection, over hanging restorations, cheek biting etc. Continuous irritation of these factors causes underlying connective tissue to become hyperplastic and proliferation of granulation tissue occurs. That leads to formation of pyogenic granuloma [2].

Pyogenic granuloma is classified into two types namely lobular capillary haemangioma and non lobular capillary hemangioma depending upon difference in their histological features. Lobular capillary hemangioma shows large number of proliferating blood vessels and non lobular capillary hemangioma shows presence of dilated capillary channels and aligns with endothelial cells. Histologically, pyogenic granuloma is more likely a granulomatous lesion. Connective tissue shows dense infiltration of chronic inflammatory cell infiltration, fibroblast and budding capillaries [8].

The term pyogenic granuloma is being used now to describe this lesion is considered to be a misnomer. Due to its vascularity, the term “Telangiectatic Granuloma” has also been proposed [9].

Differential diagnosis of pyogenic granuloma includes peripheral giant cell granuloma, peripheral ossifying fibroma, hemangioma, angiosarcoma [10].

Treatment plan includes the complete surgical removal of lesion. Etiologic factor for pyogenic granuloma is also removed. There are many other treatment modalities are available such as Nd:Yttrium-aluminium-granet laser, cryosurgery, carbon dioxide laser. Incomplete removal of lesion may lead to recurrence of lesion [6].

Conclusion-

PG is a benign tumour of oral cavity usually does not attain a large size. Careful diagnosis is necessary to differentiate this lesion from vascular lesions. Complete excision is required to avoid recurrence of lesion.

References

1. Sangamesh NC, Poornima B, Vaidya KC, Sakri SB. Extralingival pyogenic granuloma: A rare case report. J Sci Soc 2013;40:49-51
2. Sadiq S, Ramesh A, Bhandary R, Shetty P. Pyogenic Granuloma-A Case Report. Journal of Health and Allied Sciences NU. 2016 Dec;6(04):84-6.
3. Kurian, Dr. Bobby, Dr. Sasirekha, and Dr. Ebenezer. "Pyogenic Granuloma- a Case Report and Review." International Journal of Dental Sciences and Research 2.3 2014: 66-68.
4. Ganesan A, Kumar NG, Azariah E, Asokan GS. Oral pyogenic granuloma: A case report and a comprehensive review. SRM J Res Dent Sci 2015;6:257-60
5. Saikhedkar R, Shrivastava S, Melkundi M, Viswanathan V. Pyogenic granuloma--a case report. International Journal of Dental Clinics. 2011 Jul 1;3(3):87-9.
6. Jafarzadeh H, Sanatkhan M, Mohtasham N. Oral pyogenic granuloma: a review. J Oral Sci. 2006;48(4):167-75.
7. Pyogenic granuloma of the gingiva: a case report. International Journal of Contemporary Medical Research 2018;5(11):K1-K3.
8. A. Epivatianos, D. Antoniadis, T. Zaraboukas et al., "Pyogenic granuloma of the oral cavity: comparative study of its clinicopathological and immunohistochemical features," Pathology International. 2005;55(7)391–397.
9. Marla V, Shrestha A, Goel K, Shrestha S. The Histopathological spectrum of pyogenic granuloma: A Case Series. Case Rep Dent. 2016; 2016:ID1323798, 6p.
10. Kamal R, Dahiya P, Puri A. Oral pyogenic granuloma: Various concepts of etiopathogenesis. J Oral Maxillofac Pathol 2012;16:79-82.

Corresponding author:

Dr. Komal B. Dipke

PG Student

Dept. of Oral Maxillofacial Pathology

Email id: dipkekomal20@gmail.com

How to cite this Article: Dipke KB, Patil NN, Murgod VV, Rakkaraddi M, Kharwade N, Shirdhonkar A. Pyogenic granuloma - A case report. Journal of Interdisciplinary Dental Sciences, 2022; Jan- Jun 11(1):14-17