

**ORAL MUCOCELE: A CASE REPORT****Dr.Rohini Divekar<sup>1</sup>, Dr.Suchita Dake<sup>2</sup>, Dr. Bushra Khan<sup>3</sup>, Dr. Deepa Raut<sup>4</sup>****Post Graduate Student <sup>1,2,3</sup>, Prof& HOD <sup>4</sup>**

Department of Oral Medicine &amp; Radiology, Saraswati Dhanwantari Dental College &amp; Hospital &amp; Postgraduate Research Institute, Parbhani, Maharashtra, India.

**ABSTRACT:**

The Mucoceles are benign mucous containing cystic lesions of salivary gland mainly of traumatic origin. The wall of this cavity is formed by compressed bundles of collagen fibrils and it is filled with mucin<sup>1</sup>. Mucoceles are known to occur most commonly on the lower lip, followed by the floor of mouth and buccal mucosa being the next most frequent sites<sup>2</sup>. Mostly they are two types based on histological features which are as follows: Extravasation and retention. The treatment of choice is surgical removal of the mucocele<sup>3</sup>.

**Keywords:** Mucocele benign cystic lesions salivary gland traumatic.**INTRODUCTION:**

Cysts of the minor oral salivary glands are very common. The majority are extravasation mucoceles caused by damage to the excretory duct and pooling of mucus in the adjacent connective tissue<sup>4</sup>. Oral mucoceles are benign soft tissue masses and are clinically characterized by single or multiple, painless, soft, smooth, spherical, translucent, fluctuant nodule, which is usually asymptomatic<sup>5</sup>. Mucoceles develop by mechanisms of mucous extravasation, which generally regarded as traumatic origin or by retention phenomenon caused by obstruction or stricture of the duct of a salivary gland. Extravasation is the leakage of fluid from the ducts or acini of salivary glands in the surrounding tissues (mucus extravasation cyst); retention phenomenon

occurs as a result of a narrowed ductal opening due generally to inflammatory causes or sialolith causing ductal dilation and surface swelling. The extravasation type is a pseudocyst with extravasation of mucin into the connective tissue, while the retention type of oral mucocele is a true cyst lined by epithelium are less common, usually affection older individuals<sup>6</sup>.

**CASE REPORT:**

A 21 year old female patient reported to the Department of Oral Medicine and Radiology in Saraswati Dhanwantari Dental College and Hospital, Parbhani. She came with a chief complaint of painless swelling on right side on anterior buccal mucosa near corner of mouth. History of present illness consisted of swelling in inner aspect of cheek in relation to right canine and first premolar region since 2 to 3 months. A

detailed history elicited from the patient showed etiology to be trauma from biting. Examination of swelling showed it to be oval in shape, soft, palpable with no increase in temperature and symptomless. The lesion was 1.5 – 2 cm in diameter and placed in the inner aspect of buccal mucosa of the lower lip. Fig.1.

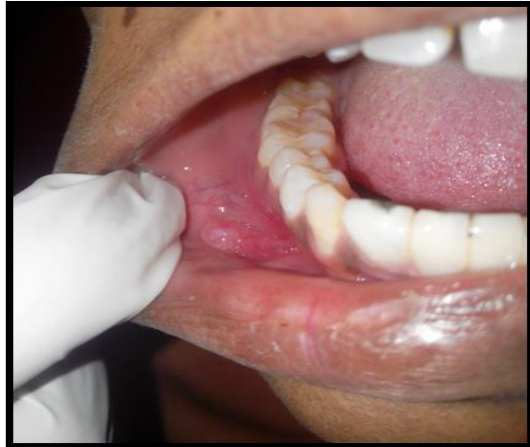

Fig.1

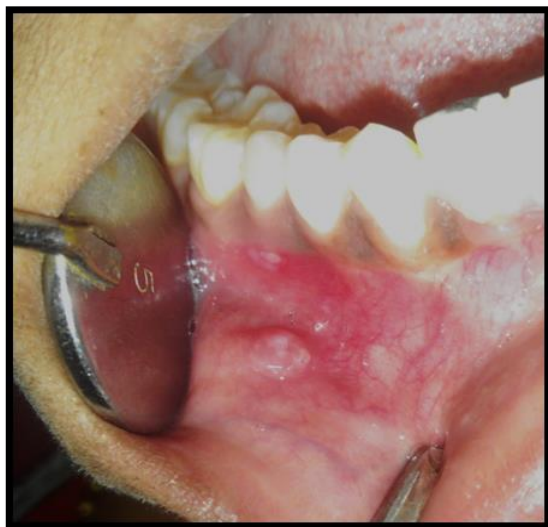

Fig.2.

The patient did not have any difficulty in speech. The lady had all the teeth present with calculus and no obvious malocclusion. The lab investigations like HB,CBC and CT,BT were conducted and the values were found to be normal. The differential diagnoses were Oral ranula, Oral lymphangioma Oral haemangioma and Minor aphthous ulcers. The Final diagnosis was formulated as a Mucocele on the basis of the history of the Lip biting habit, clinical features and histopathological findings. The treatment planning consisted of the surgical removal of the lesion. Under local anesthesia an incision was placed horizontally (fig.3.) ; therefore splitting the overlying mucosa and separating the lesion from the mucosa. The Mucocele was resected from the base so that chances of reoccurrence are less, sutures were placed. Regular recall and checkup for the reoccurrence of the lesion was done.

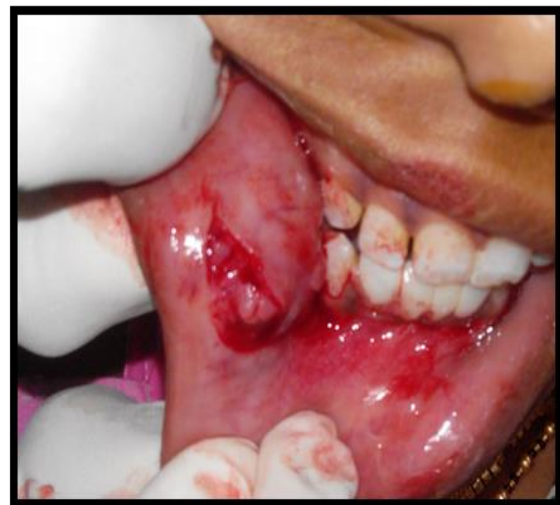

Fig.3.

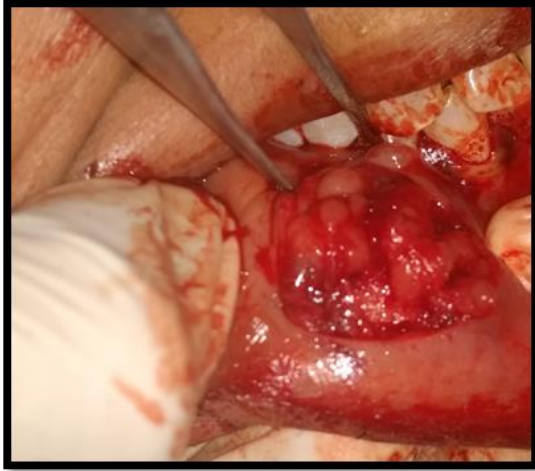


Fig.4.

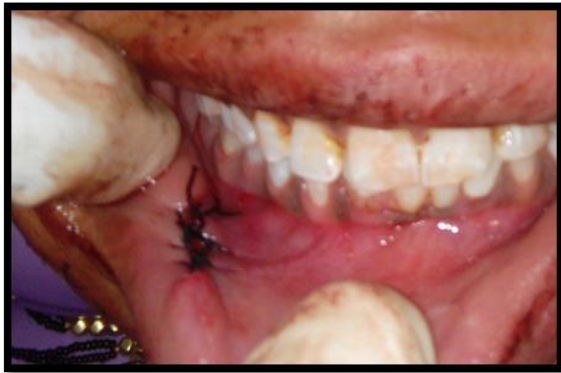

Fig.5.

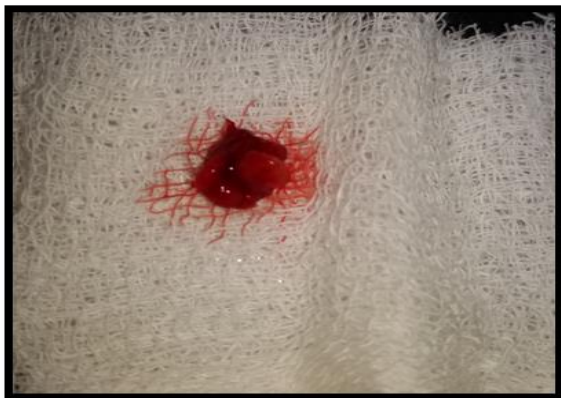

Fig.6.

## HISTOPATHOLOGY:

Histopathological report -

H & E section shows cystic lumen lined by thin capsule composed of thin collagen fibers, blood vessels & chronic inflammatory cells. Peripherally salivary gland lobules & muscle bundle are noted. Features on clinical correlation are suggestive of `` Mucus extravasations cyst ``

## DISCUSSION:

Mucocele may be located either as a fluid filled vesicle or blister in the superficial mucosa or as a fluctuant nodule deep within the connective tissue<sup>5</sup>. The remainder occurs in the cheek, palate, floor of the mouth, tongue, and retromolar fossa, which are regions where mucous glands are normally found<sup>8</sup>. The clinical presentation may vary depending on the depth of the lesion. The lesions are located directly under the mucous membrane (superficial mucocele) or in the upper submucosa (classical mucocele)<sup>12</sup>. The extravasation type undergoes three evolutionary:

- Phases I: In the first phase, there is spillage of mucus from salivary duct into the connective tissue.
- Phase II: In the second phase, it is the resorption phase in which granulomas appear due to the presence of histiocytes, macrophages, and giant multinucleated cells associated with foreign body reaction.
- Phase III: In the third phase, there is formation of pseudocapsule without epithelium around the mucosa<sup>11</sup>. The various differential diagnosis are Blandin and Nuhn

mucocele, Benign or malignant salivary gland neoplasm, Oral Hemangioma, Oral Lymphangioma, Venous varix, Soft irritation fibroma, Gingival cyst, Soft tissue abscess. Superficial mucoceles may be confused with Cicatricial pemphigoid, Bullous lichen planus and Minor aphthous ulcers<sup>5</sup>. The history, clinical findings and histopathological evaluation lead to the diagnosis of a Superficial Mucocele. The localization and determination of the origin of the lesion can be done by Computed tomography scanning and magnetic resonance imaging<sup>5</sup>. Surgical excision with removal of the involved accessory salivary gland has been suggested as the treatment both the Mucocele are treated in same manner. Acc to Pedron et al, mucocele can be treated by conventional surgery, cryo therapy, carbon dioxide laser surgery or Nd:Yag laser vaporisation. The diode laser can be useful if the lesion contains a vascular area which could result in post treatment hemorrhage. Fibrotic lesions or lesions which do not contain any pigment may be more effectively removed using the Erbium laser<sup>5</sup>.

## **CONCLUSION:**

The nonneoplastic diseases of salivary gland pose a diagnostic and therapeutic challenge to the clinician because of close resemblance of clinical presentation despite different etiologies such as reactional inflammatory processes, metabolic and immune disorders, infections and iatrogenic responses. Thus, clinical knowledge of oral lesions, as well as the determination of aspects related to the etiopathogenesis of these lesions, is necessary for the correct diagnosis and for the indication of appropriate treatment.

## REFERENCES:

1. Kariya PB, Dagrus K, Bohra S, Bargale S. Oral Mucocele In Pediatric Patient: A Case Report And Review Of Literature. EJDTR, 2014 3(3), 234-236
2. Singh N, Chandra P, Agarwal S. Oral Mucocele : A Case Report. journal of dentofacial sciences 2014; 3(1): 47-50.
3. Nallasivam KU, Sudha BR. Oral mucocele: Review of literature and a case report. J Pharm Bioall Sci 2015;7:S731-3.
4. Eveson J W, ORAL SURG ORAL MED OWL PATHOL 1988;66:318-22
5. More CB, Bhavsar K, Varma S, Tailor M. Oral mucocele: A clinical and histopathological study. J Oral Maxillofac Pathol 2014;18:72-7.
6. Shirodkar G, Tungare S. Oral Mucocele: A Report of Two Cases and Literature Review. IJSS Case Reports & Reviews 2016;3(1):7-11.
7. Chaitanya P, Praveen D, Reddy M. Mucocele on Lower Lip: A Case Series. Indian Dermatology Online Journal. 2017;8(3):205-20
8. Senthilkumar B, Mahabob MN. Mucocele: An unusual presentation of the minor salivary gland lesion. Journal of Pharmacy & Bioallied Sciences. 2012;4(Suppl 2):S180-S182.
9. Ramkumar S, Ramkumar L, Malathi N, Suganya R. Excision of Mucocele Using Diode Laser in Lower Lip. Case Rep Dent. 2016;2016:1746316. doi: 10.1155/2016/1746316. Epub 2016 Dec 21.
10. Bermejo A, Aguirre J M, María R, Murcia. Oral Surg Oral Med Oral Pathol Oral Radiol Endod 1999;88:469-72

### Corresponding Author Details:

Dr. Rohini Divekar, PG Students,  
Department of Oral Medicine & Radiology,  
Saraswati Dhanwantari Dental College &  
Hospital & Post-Graduate Research Institute,  
Parbhani, Maharashtra, India.